

Co-Existence of Synodontia & Talon Cusp in Mandible: A Rare

Mohapatra S^{1*}, Pareek S², Arora KS³, Verma A⁴, Mishra D⁵ and Yadav V⁶

¹Department of Oral Medicine and Radiology, SCB Dental College, Cuttak, Odisha, India

²Department of Oral Pathology and Microbiology, Institute of Dental Sciences, Bhubanswar, Odisha, India

³Department of Oral Medicine & Radiology, Bhojia Dental College & Hospital, Bhud, Baddi, Himachal Pradesh, India

⁴Senior Lecturer, Department of Oral Pathology and Microbiology, Rajasthan Dental College and Hospital, Jaipur, Rajasthan, India

⁵Department of Periodontology and Oral Implantology, Kalinga institute of Dental Sciences, Bhubneshwar, Odisha, India

⁶Department of Oral Medicine and Radiology Eklavya Dental College and Hospital, Kotputli, Rajasthan, India

Volume 1 Issue 2- 2018

Received Date: 23 June 2018

Accepted Date: 20 July 2018

Published Date: 26 July 2018

1. Abstract

Aim: The aim of reporting this case is to bring to light a different kind of tooth developmental anomaly very rarely reported in literature.

Case Report: Synodontia and Talon cusp are rare developmental anomalies present in human dentition. Talon cusp is most commonly seen on the palatal surfaces of the permanent maxillary anteriors while synodontia is seen in primary anterior dentition. The present case reports an unusual case of Synodontia of mandibular anteriors with talon cusp.

3. Conclusion: Talons cusp as well as fusion are rare anomalies individually with the treatment differing from case to case. The combination of both the anomalies is even rarer, with a varying treatment plan.

2. Key words

Dentition; Fusion; Synodontia;
Talon's cusp

3. Introduction

"Fusion" and "Gemination" are the terms used to describe joint and double formation of teeth. It is difficult to differentiate clinically between fusion and gemination. A fused/double tooth is a developmental anomaly formed due to fusion of two adjacent tooth buds or germination of single bud during proliferation stage of tooth development [1].

It is mostly seen in primary dentition with a prevalence of 0.5% & least in permanent dentition with a prevalence of 0.1% [2]. However, reports of its distribution according to gender, race and location are conflicting in literature. The term "synodontia" was coined by Dejonge to describe adjacent teeth that fuse during development [3].

The etiology is diverse. Many believe that this alteration occurs due to physical forces that put developing teeth in contact, thus producing necrosis of the epithelial tissue that separates them, leading to fusion [4,5].

It is also said that environmental factors & thalidomide may also play a role in the etiology of fusion. Knudsen in his study found out that treating animals with trypan blue and high doses of Vi-

tamin A can cause this anomaly [5].

A fused tooth usually has two separate root canals and a single wide crown. Clinically, the crowns of the teeth appear to be joined together, with a small groove between the mesial and distal sections [6].

Talon cusp is a dental anomaly which presents as an accessory cusp-like structure projecting from the cingulum area of maxillary or mandibular anterior teeth in either dentitions [7]. It was first reported by Mitchell in 1892 and then named as Talon cusp by Mellor and Ripa [8]. It might also present as pyramidal, conical, or teat like.

Talon cusp is a rare dental anomaly, especially when it occurs on mandibular teeth. It affects both dentitions; lingual aspect of the maxillary incisor being the most frequently involved tooth. Facial talon cusps are rare. Males are affected more than females. It may appear as an isolated trait or associated with various syndromes such as Rubinstein Taybi syndrome, Mohr syndrome, Sturge Weber syndrome, incontinentia pigmenti, and Ellisvan Creveld syndrome [9,10].

The etiology of Talon's cusp is multifactorial consisting of both

*Corresponding Author (s): Karandeep Singh Arora, Department of Oral Medicine & Radiology, Bhojia Dental College & Hospital, Bhud, Baddi, Himachal Pradesh, India, Tel: 7597559999; E-mail: drkarananora@yahoo.com

genetic and environmental factors. It is caused by outward folding of inner enamel epithelial cells and a transient focal hyperplasia of the mesenchymal peripheral cells of dental papilla [7]. Reports on bilateral occurrence of talon cusp in twins, siblings or parents suggest a genetic component in the etiology.

This case report presents a rare case of lingual talon cusp on double teeth involving permanent mandibular central incisors.

4. Case Report

A 16 year old male patient reported to Department of Oral Medicine & Radiology for routine dental examination with a non – contributory medical history. His mother reported no history of medication, illness or complication during pregnancy. General physical examination was also non-contributory. Intra oral examination revealed abnormality with the mandibular left central (#tooth 31) and lateral incisor (#tooth 32). On inspection initially it was observed that there was complete fusion of both the teeth (**Figure 1**). Further it was observed that in addition to the fusion there was an eagle like extension on the lingual surface between #tooth 31 and #tooth32 indicating the presence of talon’s cusp (**Figure 2**).

An intra-oral periapical radiograph for both the teeth was taken which revealed a radio-opaque area between the crown portion of both the teeth. Further, radiograph revealed no interdental space in between the teeth suggestive of fusion (**Figure 3**).

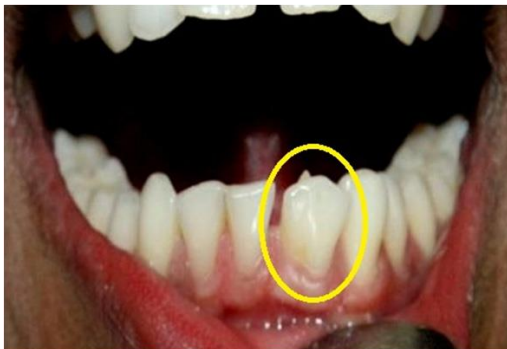

Figure 1: Fusion of mandibular left central and lateral incisors (encircled).

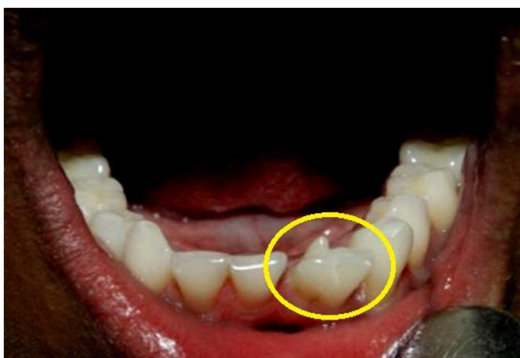

Figure 2: Talon’s cusp on the lingual side of the 2 fused teeth (encircled)

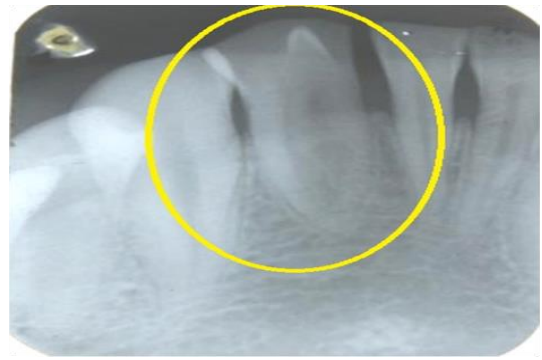


Figure 3: Intra-oral periapical radiograph of the specific region (encircled)

4. Discussion

Both double teeth & talon cusp are dental anomalies of shape which arise during the morpho-differentiation stage of tooth development which has multifactorial etiology.

Fusion of teeth is very often confused with gemination. Fusion takes place when two teeth buds join with each other whereas on the other hand, gemination happens from the division of single tooth germ by invagination during the growth cycle [11]. Fusion between two teeth always involves dentin and may result in an abnormally large tooth than normal and the union of both crowns or only of the roots [11,12].

Talon cusp is a rare abnormality which most frequently affects the maxillary permanent incisor which in this case report was in mandibular permanent incisor hence being a rare finding. It comprises of enamel, dentine and sometimes varying quantity of pulp.. Talon’s cusp can be classified on the degree of formation and extension and divided talon’s cusps into three categories [13].

- Type 1 (True talon): well-delineated additional cusp that predominantly projects from the palatal or lingual surface of an anterior tooth and extends half way from CEJ to the incisal edge.
- Type 2 (Semi talon): An additional cusp of a millimeter or more but extending less than half the distance from CEJ to incisal edge. It may blend with palatal surface or strand away from the crown.
- Type 3 (Trace talon): Enlarged cingulum and may present as conical bifid or tubercle shaped.

According to the above given classification, we graded our case as a Type 1 talon cusp.

Treatment of fused teeth & talon cusp also differs according to case. In case of non carious, no special treatment is required. Restorative & endodontic procedures are advised in case of carious exposure [14].

No treatment is required in a small asymptomatic talon’s cusp. In case of large anomalous cusp clinical problems such as occlusal interference, displacement of the affected tooth, irritation of the

tongue during the speech and mastication, attrition of the tooth and periodontal problems treatment is required [14]. In case of a serious problem, complete removal of cusp is done along with root canal therapy [15].

In the present case, the patient was totally asymptomatic so no treatment procedure was carried out with respect to mandibular left central and lateral incisor.

5. Conclusion

Talons cusp as well as fusion are rare anomalies individually with the treatment differing from case to case. The combination of both the anomalies is even rarer, although the treatment would be pretty much the same. Oral prophylaxis was done for this patient as there were no presenting esthetic complaints and was asked for regular follow up.

References

1. Pindborg JJ. Pathology of the dental hard tissues. Philadelphia: W.B Saunders Co. 1970; 4755.
2. Spounge JD. Oral pathology. Saint Louis: C.V Mosby Co. 1973; 1356.
3. Dejonge TE. Beschouwingen Over DE Syndontie. T Tandheelk. 1955; 62: 828.
4. Milano M, Seybold SV, Mc Candless G, Cammarata R. Bilateral fusion of mandibular primary incisors: report of case. J Dent Child. 1999; 66: 2802.
5. Knudsen PA. Fusion of upper Incisors at bud or cap stage in mouse embryos with exencephaly induced by hypervitaminosis A. Acta Odont Scand. 1965; 23: 391409.
6. Velasco LFL, Araujo FB, Ferreira ES, Velasco LEL. Esthetic and functional treatment of a fused permanent tooth: a case report. Quintessence Int. 1997; 28: 677–680.
7. Shafer WG, Hine MK, Levy BM. A Textbook of Oral Pathology. 4th ed. Philadelphia: WB Saunders. 1983; 41.
8. Mitchell WH. Case report. Dent Cosmos. 1892; 34: 1036.
9. Sumer AP, Zengin AZ. An unusual presentation of talon cusp: A case report. Br Dent J. 2005; 199: 42930.
10. Kulkarni VK, Choudhary P, Bansal AV, Deshmukh J, Duddu MK, Shashikiran ND. Facial talon cusp: A rarity, report of a case with one year follow up and flashback on reported cases. Contemp Clin Dent 2012; 3(Suppl 1): S1259.
11. Shashikiran ND, Babaji P, Reddy VV. Double facial and a lingual trace talon cusps: A case report. J Indian Soc Pedod Prev Dent. 2005; 23: 8991.
12. Brook AH, Winter GB. Double teeth. A retrospective study of 'geminated' and 'fused' teeth in children. Br Dent J. 1970; 129: 12330.
13. Hattab FN, Yassin OM, Al-Nimri KS. Talon cusp in permanent dentition associated with other dental anomalies: review of literature and reports of seven cases. J Dent Child. 1996; 63(5): 368–76.
14. Da Costa GC, Chalakkal P. Bilateral Complete and Incomplete Fusion of Incisors and its Management. Contemp Clin Dent. 2017; 8(1): 171-4.
15. Sharma G, Nagpal A. Talon Cusp: A Prevalence Study of Its Types in Permanent Dentition and Report of a Rare Case of Its Association with Fusion in Mandibular Incisor. J Oral Dis. 2014.