

Severe Intracranial Subdural Hematoma Following Epidural Anaesthesia in Pregnancy: A Case Report

Casimir F^{1*}, Serge N², Benjamin O³, Yakan S⁴, Sandio A⁵ and Daniel E H⁶

¹Neurosurgery Department CURY, Cameroon

²Anesthesiology & Reanimation, CURY, Cameroon

³Neurosurgery Department, University of Douala, Cameroon

⁴Internal Medicine Department CURY, Cameroon

⁵Detroit Medical Center, Cameroon

⁶Orthopedics Surgery Department, University of Yaounde I, Cameroon

* Corresponding author:

Casimir Fankem,
Neurosurgery Department CURY, Cameroon,
E-mail: casimirfankem@yahoo.fr

Received: 20 Dec 2022

Accepted: 17 Jan 2023

Published: 27 Jan 2023

J Short Name: ACMCR

Copyright:

©2023 Casimir F. This is an open access article distributed under the terms of the Creative Commons Attribution License, which permits unrestricted use, distribution, and build upon your work non-commercially

Citation:

Casimir F, Severe Intracranial Subdural Hematoma Following Epidural Anaesthesia in Pregnancy: A Case Report. Ann Clin Med Case Rep. 2023; V10(11): 1-3

Keywords:

Postural Puncture Headache; Anaesthesia;
Monoamniotic-mono chorionic

1. Abstract

Severe headache is one of the quite common complication after a dural puncture procedure be it diagnostic (lumbar puncture) or unintentional (e.g., after epidural anaesthesia). Knowing that Postural Puncture Headache (PDPH) most often becomes the culprit in most cases, many severe and serious etiologies should be assessed though it's frequently rare due to other causes of headache after Dural puncture. (e.g., tension headache, migraine, and PDPH) known as the most common. It's very easy to misdiagnose PDPH from PEISH due to the clinical similarities in manifestation. However, we are presenting a case of this rare complication by presenting the difference between PDPH and PEISH. This 25-year-old young woman with epidural anaesthesia. The patient described some vague feelings, decreased foetal movement earlier in the morning that day prior to the visit, complained of severe headache immediately following receiving epidural anaesthesia for labour induction. The patient was initially diagnosed with PDPH, and a blood patch was placed which provided complete resolution of the headache only for two days. Computed tomography of the brain revealed a major mass described as subdural hematoma over the left frontal convexity. Surgical management was recommended and a close follow up was observed two weeks later a control CT scan was requested and showed complete and spontaneous resolution of the hematoma.

In patients with recurrence or change in the pattern of the headache, persistence of headache despite treatment, and presence of neurological dysfunction following epidural anaesthesia, suspicion of intracranial etiologic must be raised. Therefore, knowledge of this condition and differentiating it from PDPH is necessary to avoid misdiagnosis and futile attempts of treatment.

2. Introduction

Epidural block is one of the major techniques used in anaesthesia. In general, majority of anaesthetist physicians believe it's the most appropriate and safe procedure that can help patients in adequate analgesia mostly in the lower part of the body [1]. It is employed in a broad range of procedures, mostly during childbirth in obstetric procedures [1]. However, it is important to mention that it can be the source of some major complications such as intracranial subdural hematoma [4-6]. Many patients with major subdural hematoma following epidural block can be mistakenly diagnosed with postural puncture headache (PDPH). While intracranial subdural hematoma following epidural anaesthesia is very rare almost impossible (1:500,000) [3], it is very important and critical for every physician to understand and make a clear difference between PDPH, as subdural hematoma can potentially lead to significant morbidity and mortality.

3. Case Presentation

A 25-year-old female gravida 1 (G1) para 1 (P1) comes to the hospital for prenatal follow-up visit at 20 weeks' gestation of mono-amniotic-mono chorionic pregnancy. The patient described some vague feelings, decreased foetal movement earlier in the morning that day prior to the visit. She was admitted because of severe headache intensity 7/10. Patient described difficulty sitting and loss of focus. 2 weeks later, the intensity of headache went up to 9/10 generalized with photophobia and was not tolerating anti-inflammatory medication. A scan was done that showed sub-acute subdural hematoma with rebleeding which led to the indication of surgery. She benefited from craniotomy and evacuation. She was discharged on day 5 post-op and was advised to follow up for wound dress. Body surface ultrasound showed normal cardiac motion for foetus. She was then admitted to the hospital for C-section. The patient received epidural anaesthesia and had since complained of postural headache and severe neck pain that radiated bilaterally to shoulders and mid upper back. She stated that the headache is worsened by sitting upright and by moving her head to the right or to the left and improved when she lies down. She denies any fever, vomiting, confusion, or visual changes. Aside from neck pain, right lower extremity weakness, and lightheadedness. On physical examination, the patient was alert and oriented with no remarkable neurological signs except for mild weakness in the right lower extremity (4+/5). She was afebrile with normal body temperature, blood pressure, pulse, and respiratory rate (37°C (97.88°F), 112/84 mm Hg, 81/beat per minute (bpm), and 17/min, respectively).

The patient was initially diagnosed with PDPH, and an epidural blood patch was then placed the next day. The headache resolved, but she was not able to move her neck due to pain. Analgesic and muscle relaxant were recommended which she claims helped alleviate the pain partially. An MRI of the cervical, thoracic, and lumbar spine was obtained and showed changes related to her recent blood patch; however, there was no significant canal stenosis. Brain CT scan with no contrast (Figures 1A, 1B) revealed left frontal convexity subdural hematoma measuring 10 mm in thickness with no midline shift, herniation, or associated mass effect.

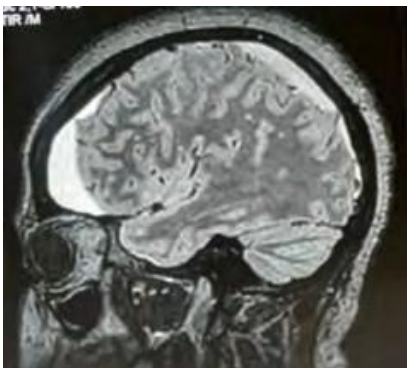


Figure 1A: Cerebral MRI represented on Sagittal Frame

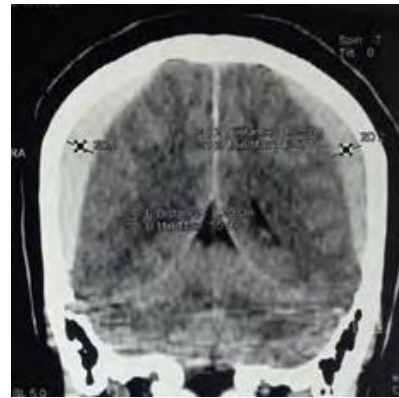


Figure 1B: Cerebral Scan Represented on Coronal Frame

4. Discussion

Epidural anesthesia procedure mostly used in obstetrical by anesthesiologist is well established. Over all, the complications related to the neuraxial anesthesia have been proven to be unusual [10]. Furthermore, certain adverse manifestations such as intracranial subdural hematoma are recognized as major issues and can be potentially fatal if misdiagnosed or neglected early and addressed promptly. The number one incidence of Postepidural Intracranial Subdural Hematoma (PEISH) is still not clear enough because of the uncertainty nature of the data collected on various cases. However, an incidence of 1:500,000 has been estimated based on a large questionnaire involving 203 obstetric units in the United Kingdom [2]. Despite the great variation in reported incidence, acute subdural hematoma is not uncommon after dural puncture, especially in anticoagulated patients and patients with coagulation abnormalities. In such cases, a CT scan should be always obtained. Although both complications share similar clinical characteristics, PDPH is a more frequent sequel than PEISH. This may have contributed to the initial misdiagnosis of PDPH in our case. In a survey of 18,337 epidural blocks, 0.91% had accidental dural puncture with more than 88% of these developed PDPH [8,9]. After all, both PDPH and PEISH should be considered in any patient with postdural puncture headache.

In addition, PDPH and PEISH are very similar with respect to pathophysiology [2,4]. Cerebrospinal fluid (CSF) leakage typically occurs upon puncture of the dura mater. Excessive loss of the CSF leads to marked reduction in the CSF volume and subsequent intracranial hypotension [2,10]. This results in traction on the intracranial, pain-sensitive structures causing the headache. Stretching of the dural bridging veins (which are typically dilated to compensate for the CSF loss according to Monro-Kellie hypothesis) due to caudal displacement of the brain may lead to tearing in the wall of subdural veins and consequently leaking blood in the subdural space with hematoma formation [2,3,6,9]. In our patient, the hematoma was most likely the result of an unintentional dural puncture during the epidural block and probably continuous CSF leakage thereafter (Figure 2).

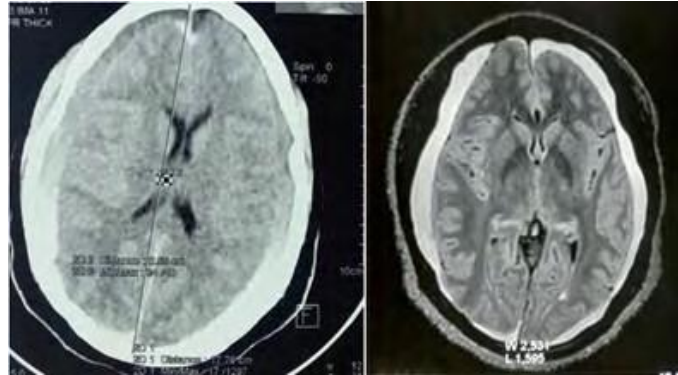


Figure2: Bi-lateral and Pan- hemispheric subacute subdural hematoma.

5. Conclusion

As matter of fact, the concept of major mass of intracranial subdural hematoma consequent to epidural anaesthesia is a clinical concern and a serious complication since it is commonly misdiagnosed as PDPH. The index of suspicion for PEISH should be high, as this condition is a serious life-threatening and can result in definite neurological sequelae. Nevertheless, knowledge of the clinical features and clues of PEISH and early diagnosis are of paramount importance.

References

1. Kale A, Emmez H, Pişkin Ö, Durdağ E. Postdural puncture subdural hematoma or postdural puncture headache? two cases report. *Korean J Anesthesiol.* 2015; 68: 509-12.
2. Zeidan A, Farhat O, Maaliki H, Baraka A. Does postdural puncture headache left untreated lead to subdural hematoma? Case report and review of the literature. *Int J Obstet Anesth.* 2006; 15: 50-8.
3. Ramírez S, Gredilla E, Martínez B, Gilsanz F. Bilateral subdural hematoma secondary to accidental dural puncture. *Braz J Anesthesiol.* 2015; 65: 306-9.
4. Gaucher DJ Jr, Perez JA Jr. Subdural hematoma following lumbar puncture. *Arch Intern Med.* 2002; 162: 1904-5.
5. Bishop TM, Elsayed KS, Kane KE. Subdural hematoma as a consequence of epidural anesthesia. *Case Rep Emerg Med.* 2015; 2015:597942.
6. Liang MY, Pagel PS. Bilateral interhemispheric subdural hematoma after inadvertent lumbar puncture in a parturient. *Can J Anaesth.* 2012; 59: 389-93.
7. Sprigge JS, Harper SJ. Accidental dural puncture and postdural puncture headache in obstetric anaesthesia: presentation and management: a 23-year survey in a district general hospital. *Anaesthesia.* 2008; 63: 36-43.
8. Turnbull DK, Shepherd DB. Post-dural puncture headache: pathogenesis, prevention and treatment. *Br J Anaesth.* 2003; 91: 718-29.
9. Bezov D, Lipton RB, Ashina S. Post-dural puncture headache: part I diagnosis, epidemiology, etiology, and pathophysiology. *Headache.* 2010; 50: 1144-52.
10. Vandam LD, Dripps RD. Long-term follow-up of patients who received 10,098 spinal anesthetics; syndrome of decreased intracranial pressure (headache and ocular and auditory difficulties). *J Am Med Assoc.* 1956; 161: 586-91.