

# Annals of Clinical and Medical Case Reports

Research Article

ISSN 2639-8109 | Volume 6

## Intraventricular Neurocytoma a Series of 10 Cases and Review of Literature

Bouaita K<sup>1,2\*</sup>, Atroune L<sup>2</sup>, Benalleg S<sup>2</sup> and Habchi N<sup>2</sup>

<sup>1</sup>Neurosurgery department Cherchell hospital, Algeria

<sup>2</sup>Neuroplasticity and glial tumors laboratory, Algeria

### \*Corresponding author:

Kamel Bouaita,  
Neurosurgery department Cherchell hospital,  
Neuroplasticity and glial tumors laboratory,  
Algeria, E-mail: nawelmedbio@yahoo.fr

Received: 16 Apr 2021

Accepted: 10 May 2021

Published: 15 May 2021

### Copyright:

©2021 Bouaita K. This is an open access article distributed under the terms of the Creative Commons Attribution License, which permits unrestricted use, distribution, and build upon your work non-commercially.

### Citation:

Bouaita K. Intraventricular Neurocytoma a Series of 10 Cases and Review of Literature. Ann Clin Med Case Rep. 2021; V6(14): 1-5

### Keywords:

Central neurocytoma; Intraventricular; Immunohistochemistry.

### 1. Abstract

Central neurocytoma (CN) is a benign brain tumor of intraventricular site; According to the World Health Organization (WHO) 2016, it is categorized as grade II. We report a series of 10 cases that were diagnosed with CN by immunohistochemistry of surgical specimens at our hospital. The Average age of our cases was 22 years old; and the male: female ratio was 7:3; Presenting symptoms were related to intracranial hypertension; the typical appearance of a CN was observed in all of the masses; heterogeneous signal with enhancement after injection of gadolinium; the lesions were located in the lateral ventricle. All our patients underwent two surgeries: first the placement of a ventriculo-peritoneal bypass valve followed by surgical removal of the tumor; the postoperative follow-up was favorable and the postoperative cerebral MRI was satisfactory. Surgical resection is the treatment of choice for intraventricular neurocytomas, with a generally favorable postoperative prognosis without tumor residue or recurrence; however, the approach has to be tailored specifically to each case.

### 2. Introduction

Central neurocytoma (CN) is a benign brain tumor of intraventricular site; According to the World Health Organization (WHO) 2016, it is categorized as grade II [1]. Extra ventricular neurocytoma location is exceptionally rare [2,3]. It is rare, accounting for 0.1 to 0.5% of central nervous system tumors, and 10% of intraventricular tumors. It most often affects young adults; The main differential diagnosis is with intraventricular ependymomas and

oligodendrogliomas, and CN mimic them histologically; The diagnosis of CN requires evidence of neuronal differentiation, demonstrated by electron microscopy or by positive immunohistochemical (IHC) staining for synaptophysin or other markers. MRI is the exam of choice for making a diagnosis and Its prognosis is generally favorable after adequate surgical removal, although some patients with recurrence and cerebrospinal dissemination have been reported [4,5].

### 3. Materiel and Methods

We report a series of 10 cases that were diagnosed with CN by immunohistochemistry of surgical specimens at our hospital. These cases were retrospectively analyzed with reference to their clinical records, neuroradiological findings, histopathological results, and methods of management. Clinical and radiological follow-up was available for our patients and clinical outcomes were recorded.

### 4. Result

The Average age of our cases was 22 years old; and the male: female ratio was 7:3; the average diagnostic time was 1.5 years; Presenting symptoms were related to intracranial hypertension; headache, blurred vision and one patient had no symptoms.

The typical appearance of a CN was observed in all of the masses; heterogeneous signal with enhancement after injection of gadolinium; the lesions were located in the lateral ventricle (body of the right lateral ventricle) (Fig 01).

All our patients underwent two surgeries: first the placement of a ventriculo-peritoneal bypass valve followed by surgical removal

of the tumor; the postoperative follow-up was favorable and the postoperative cerebral MRI was satisfactory.

We used three Approaches: 05 patients benefited from trans-frontal trans-ventricular approach; 03 trans-parietal trans-ventricular approach and 02 anterior trans-callosal approach.

## 5. Discussion

Central neurocytoma is a benign tumor of the central nervous system of the intraventricular site; that originate from bi-potential progenitor cells in the periventricular matrix, Reports showed proofs for both glial and neuronal differentiation in many tumors [1, 6, 7]. It was first described in 1982 by Hasboun et Al, as a well-differentiated tumor of neuronal origin [3] and it is now classified as a grade II central nervous system tumor according to the World Health Organization classification system [1]

CN represents 0.1 to 0.5% of intracerebral tumors and 10% of intraventricular tumors [8,9,10]. It occurs most commonly in young adults in their thirties show a slight male predominance [11,12]; A Surveillance Epidemiology and End Results (SEER) data report of 229 CNs were more often female (53%) versus male (44%) (13). In contrast, Choudhari et al., in an extensive multidisciplinary review of published series found no gender predilection [14]. In our observations, the average age was 18 years with a sex ratio equals to 1 (Figure 1).

Patients frequently present with symptoms of intracranial hypertension which remains the most common reason for consultation; intense headaches resisting the usual treatment, jet vomiting and papillary edema in the fundus; these symptoms are attributed to increased intracranial pressure secondary to obstructive hydrocephalus. We can also see visual disturbances, seizures, memory disorders as well as walking disorders; our data support these findings, since the majority of our patients complained of headaches (6,15).

CN can also manifest itself by spontaneous intraventricular hemorrhage, neurological deficit, or even hormonal changes linked to the impairment of 3rd ventricle.

The most common site of CN is the septum pellucidum or in the walls of the lateral ventricles and have a major intraventricular component, similar to most of our cases [11,16,17]. in 25% of the cases it extend into the 3rd ventricle towards Monro's hole, and 13% of the time it reaches both lateral ventricles, Only 3% sit exclusively in the 3rd ventricle, but the extension towards the 4th ventricle remains an extremely rare possibility.

Extraventricular extension is possible and indicates a malignant transformation (cerebral hemispheres, cerebellum, spinal cord) [18].

CT scans of CN typically demonstrate an iso-intense or slightly hyperintense intraventricular mass with intratumoral calcifications which gives the gritty feel experienced by surgeons; and cystic areas within the lateral ventricles near the foramen of Monro; with

mild to moderate enhancement after gadolinium. The septum pellucidum is usually not clearly visible as the tumor is centered on the midline and results in hydrocephalus (29,20). A uni or bilateral hydrocephalus can be observed, as was the case in our cases.

Brain MRI remains the exam of choice ; typical CN MRI images are striking, an expansive process taking place in the lateral ventricle, with or without third ventricle extension, attachment to the septum pellucidum, and heterogeneous isointensity to hypointensity on T1-weighted and hyperintensity on T2-weighted sequences [21]. (The soft portion is hyperintense in T1 and T2 sequences, while cystic formations are hypointense in T1 and hyperintense in T2; T1 and T2 weighted hypointense areas may correspond to calcifications, hemorrhage or tumor neovasculisations).

In our reported observations, the appearance is typical of a central neurocytoma by its location entirely intraventricular and the presence of the three components, solid tissue, cystic and calcifications. Extraventricular extension is possible and results in hypointense images in T1 sequences and a hyperintense signal in T2 sequences overflowing on the periventricular region indicating a malignant transformation. This extension was not observed in our cases.

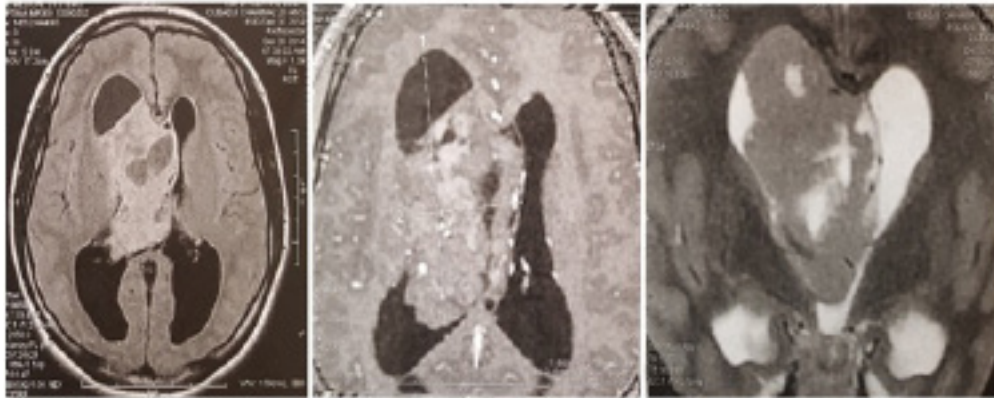The main differential diagnosis is other intraventricular tumors; ependymomas are more frequent in children and young adults and preferentially sits in the infratentorial territory; Oligodendrogliomas are seen in subjects over 40 years of age and are characterized above all by their intraparenchymal extension and the radiological appearance suggestive with their large calcifications. We also have other tumors like; subependymomas that are more often found in the 4th ventricle (60% of cases), and choroid plexus papillomas mainly affect children with their famous fern leaf appearance when they are benign; giant cell subependymal astrocytomas in tuberous sclerosis of Bourneville; While intraventricular meningiomas and intraventricular metastases are rare.

Surgical resection is the treatment of choice for intraventricular neurocytomas, with a generally favorable postoperative prognosis without tumor residue or recurrence; it is supported by most authors both for pathologic confirmation and for relief of mass effect risking hydrocephalus [22,13], however, the approach has to be tailored specifically according to anatomy and the degree of hydrocephalus; Total excision is recommended as local control is significantly more difficult in case of incomplete resection [23].

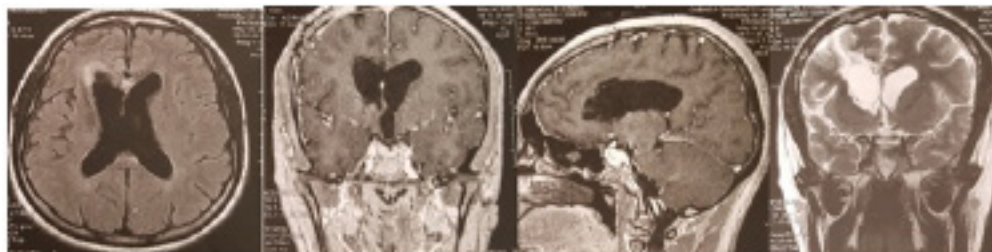
Rades et al. conducted one of the largest retrospective studies about the subject; they revealed that in patients who underwent complete resection, adjuvant radiotherapy appeared ineffective for tumor control and in overall survival. However, after incomplete resection in adults, postoperative radiotherapy resulted in improved local control and overall survival for both typical and atypical CN, in children though, radiotherapy after incomplete resection improved local control but did not significantly affect the overall survival rate

[24]; While a systematic review of 150 cases conducted by Bui TT et al. found that radiosurgery have a local control rate >90% with uncommon toxicity [25]; Still the application of postoperative radiotherapy should take into account its complications, patient age and extent of the surgical resection. There are also data published regarding other therapeutic methods to CN, such as chemotherapy, though further Investigations are needed on the subject [26,27]. In our observations, surgical excision was subtotal with good post-

operative progress, without tumor recurrence, and the patients did not benefit from chemotherapy or radiotherapy (Figure 2). Stereotactic radiosurgery (SRS) has been demonstrated to be effective in the primary treatment of CN in cases where surgical resection might be difficult, like relatively small tumors (<10 cm<sup>3</sup>) or asymptomatic tumors [25, 28-30]. Although the incidence is low, a large lesion treated with a relatively high dose in SRS may tend to develop complications [28, 30].



**Figure 1:** axial T1 and T2 weighted MRI without and with injection of gadolinium showing a process of heterogeneous signal located in the body of the left lateral ventricle which is widened. We Note after the gadolinium injection a moderate enhancement of the tumor



**Figure 2:** Post-operative brain MRI

Central neurocytoma is slow growing and its prognosis is more favorable than that of ependymoma or intraventricular oligodendroglioma when surgical excision is satisfactory. In literature Several patients with tumor recurrence have been described [31,32] and Bertalanffy et al. reported recurrence rates of 21% [33].

Intraventricular neurocytoma is a neuroepithelial tumor with neuronal differentiation. The histological analysis shows small to medium sized uniform neuronally differentiated and mitotically inactive cells with round or oval nuclei, stippled chromatin and inconspicuous nucleoli, scant cytoplasm intermingled with areas of anuclear and less dense fibrillary matrix, with polygonal cells and perinuclear “halos” which does not allow it to be differentiated from other intraventricular tumors, making oligodendrogliomas the main micro morphological differential diagnosis [34,35]. Thus we need the immunohistochemical analysis and/or electron microscopic studies which allows its diagnosis thanks to the search for positivity of anti-NSE (neuro-specific-enolase) and antisynaptophysin antibodies and negativity of GFAP to confirm the diagnosis [36,37]. Something we found in our cases.

Some previous studies have concluded that strong immunostaining for Syn is the most reliable diagnostic marker (38), and it was noted that factors like co-expression of GFAP and Syn in CN [39,40] plus increased GFAP positivity might suggest a malignant course [41].

It was also found that increased rates of recurrence are associated with high mitotic count of  $\geq 3$  % (42, 40, 43). In a multicenter study with seventy-one patients, Vasiljevic A et al. found that larger tumor volume, incomplete surgery, and a mitotic count 3 per 10 high-power fields were all predictors of a higher risk of recurrence [44]; while Sunil W. Dutta et Al in their National Cancer Database study found that Patient age ( $p < 0.001$ ), WHO grade ( $p < 0.001$ ), and medical comorbidity scores ( $p = 0.002$ ) were each independently associated with overall survival. [45].

## 6. Conclusion

Central neurocytoma is a very rare benign intraventricular tumor. They still enigmatic in many terms: origin, histopathological diagnosis and adjuvant therapies needed. They usually occur in young adult and brain MRI makes it possible to make a precise lesion

assessment and follow up. The diagnosis is histological, and the prognosis is often favorable after surgical treatment.

## References

- Komura S, Akiyama Y, Suzuki H, Yokoyama R, Mikami T, Mikuni N. Far-anterior Interhemispheric Transcallosal Approach for a Central Neurocytoma in the Lateral Ventricle. *Neurologia Medico-chirurgica*. 2019; 59(12): 511-516.
- Mahavadi AK, Patel PM, Kuchakulla M, Shah AH, Eichberg D, Luther EM, et al. Central Neurocytoma Treatment Modalities: A Systematic Review Assessing the Outcomes of Combined Maximal Safe Resection (MSR) and Radiotherapy with Gross Total Resection. *World neurosurgery*. 2020; 137: S1878-8750(20)30132-7.
- Hassoun J, Gambarelli D, Grisoli F, Pellet W, Salamon G, Pellissier JF, Toga M. Central neurocytoma. An electron-microscopic study of two cases. *Acta Neuropathol*. 1982; 56: 151-156.
- Tomura N, Hirano H, Watanabe O, J Watarai, Y Itoh, K Mineura, et al. Central neurocytoma with clinically malignant behavior. *AJNR Am J Neuroradiol*. 1997; 18: 1175-8.
- Ando K, Ishikura R, Morikawa T, et al. Central neurocytoma with craniospinal dissemination. *Magn Reson Med Sci* 2002; 1: 179-82.
- Von Deimling A, Kleihues P, Saremaslani P, MG Yasargil, O Spoerri, TC Südhof, et al. Histogenesis and differentiation potential of central neurocytomas. *Lab Invest*. 1991; 64: 585-591.
- Qian H, Lin S, Zhang M, Cao Y. Surgical management of intraventricular central neurocytoma: 92 cases. *Acta Neurochir (Wien)*. 2012; 154: 1951-1960.
- Maiuri F, R Spaziante, ML De Caro, P Cappabianca, A Giamundo, G Iaconetta, et al. Central neurocytoma: clinico-pathological study of 5 cases and review of the literature. *Clin Neurol Neurosurg* 1995; 97(3): 219-28.
- Kim DG, JG Chi, SH Park, KH Chang, SH Lee, HW Jung, et al. Intraventricular neurocytoma: clinicopathological analysis of seven cases. *J Neurosurg* 1992; 76(5): 759-65.
- Gould VE, B Wiedenmann, I Lee, K Schwechheimer, B Dockhorn-Dworniczak, J A Radosevich, et al. Synaptophysin expression in neuroendocrine neoplasms as determined by immunocytochemistry. *Am J Pathol* 1987; 126(2): 243-57.
- De Tommasi A, D'Urso PI, De Tommasi C, Sanguedolce F, Cimmino A, Ciappetta P. Central neurocytoma: two case reports and review of the literature. *Neurosurg Rev* 2006; 29: 339-47.
- Kocaoglu M, Ors F, Bulakbasi N, Onguru O, Ulutin C, Secer HI. Central neurocytoma: proton MR spectroscopy and diffusion weighted MR imaging findings. *Magn Reson Imaging* 2009; 27: 434-40.
- Song Y, Kang X, Cao G, Li Y, Zhou X, YTong Y, et al. Clinical characteristics and prognostic factors of brain central neurocytoma. *Oncotarget* 2016; 7(46):7 6291-7.
- Choudhari KA, Kaliaperumal C, Jain A, Sarkar C, Soo MYS, Rades D, et al. Central neurocytoma: a multi-disciplinary review. *Br J Neurosurg* 2009; 23(6): 585-95.
- Jaiswal S, Vij M, Rajput D, et al. A clinicopathological, immunohistochemical and neuroradiological study of eight patients with central neurocytoma. *J Clin Neurosci* 2011; 18: 334-9.
- Chen CM, Chen KH, Jung SM, et al. Central neurocytoma: 9 case series and review. *Surg Neurol* 2008; 70: 204-9.
- Mena H, Morrison AL, Jones RV, et al. Central neurocytomas express photoreceptor differentiation. *Cancer*. 2001; 91: 136-43.
- Kane AJ et al. Atypia predicting prognosis for intracranial extraventricular neurocytomas. *J Neurosurg* 2012; 116(2): 349-54.
- Schmidt MH, Gottfried ON, von Koch CS, et al. Central neurocytoma: a review. *J Neurooncol* 2004; 66: 377-84.
- Hassoun J, Söylemezoglu F, Gambarelli D, et al. Central neurocytoma: a synopsis of clinical and histological features. *Brain Pathol* 1993; 3: 297-306.
- Tacconi L, Thom M, Symon L. Central neurocytoma: a clinico-pathological study of five cases. *Br J Neurosurg* 1997; 11: 286-91.
- Patel DM, Schmidt RF, Liu JK. Update on the diagnosis, pathogenesis, and treatment strategies for central neurocytoma. *J Clin Neurosci* 2013; 20 (9): 1193-9.
- Rades D, Fehlaue F, Lamszus K, et al. Well-differentiated neurocytoma: what is the best available treatment? *Neuro Oncol* 2005; 7: 77-83.
- Rades D, Schild SE. Treatment recommendations for the various subgroups of neurocytomas. *J Neurooncol* 2006; 77: 305-9.
- Bui TT, et al. Systematic analysis of clinical outcomes following stereotactic radiosurgery for central neurocytoma. *Brain Tumor Res Treat* 2017; 5(1): 10-5.
- Buchbinder D, Danielpour M, Yong WH, et al. Treatment of atypical central neurocytoma in a child with high dose chemotherapy and autologous stem cell rescue. *J Neurooncol* 2010; 97: 429-37.
- Amini E, Roffidal T, Lee A, et al. Central neurocytoma responsive to topotecan, ifosfamide, carboplatin. *Pediatr Blood Cancer*. 2008; 51: 137-40.
- Yamanaka K, Iwai Y, Shuto T, Kida Y, Sato M, Hayashi M, et al. Treatment results of Gamma Knife radiosurgery for central neurocytoma: report of a Japanese multiinstitutional cooperative study. *World Neurosurg* 2016; 90: 300-305.
- Kim JW, Kim DG, Chung HT, Choi SH, Han JH, Park CK, et al. Radiosurgery for central neurocytoma: long-term outcome and failure pattern. *J Neurooncol* 2013; 115: 505-511.
- Aya Nakamura, Niranjana A, Lunsford LD, Kano H. Radiosurgery for Central Neurocytoma. *Prog Neurol Surg*. 2019 ; vol 34 : pp 232-237.
- von Deimling A, Kleihues P, Saremaslani P, et al. Histogenesis and differentiation potential of central neurocytomas. *Lab Invest* 1991; 64: 585-91.
- Brandes AA, Amistà P, Gardiman M, et al. Chemotherapy in patients with recurrent and progressive central neurocytoma. *Cancer* 2000; 88: 169-74.

33. Bertalanffy A, Roessler K, Koperek O, et al. Recurrent central neurocytomas. *Cancer* 2005; 104: 135-42.
34. Smith A, Smirniotopoulos J, Horkanyne-Szakaly I. From the Radiologic Pathology Archives: Intraventricular Neoplasms: Radiologic-Pathologic Correlation. *Radiographics*. 2013; 33(1): 21-43.
35. Choudhari KA, Kaliaperumal C, Jain A, Sarkar C, Soo M, Rades D, et al. Central neurocytoma: A multi-disciplinary review. *British Journal of Neurosurgery*. 2009; 23(6): 585-595.
36. Katati MJ, Vílchez R, Ros B, et al. Central neurocytoma: analysis of three cases and review of the literature. *Rev Neurol* 1999; 28: 713-7.
37. Maiuri F, Spaziante R, De Caro ML, et al. Central neurocytoma: clinicopathological study of 5 cases and review of the literature. *Clin Neurol Neurosurg*. 1995; 97: 219-28.
38. Robbins P, Segal A, Narula S, et al. Central neurocytoma. A clinicopathological, immunohistochemical and ultrastructural study of 7 cases. *Pathol Res Pract* 1995; 191: 100-11.
39. Tsuchida T, Matsumoto M, Shirayama Y, et al. Neuronal and glial characteristics of central neurocytoma: electron microscopical analysis of two cases. *Acta Neuropathol* 1996; 91: 573-7.
40. Ishiuchi S, Tamura M. Central neurocytoma: an immunohistochemical, ultrastructural and cell culture study. *Acta Neuropathol* 1997; 94: 425-35.
41. Elek G, Slowik F, Eross L, et al. Central neurocytoma with malignant course. Neuronal and glial differentiation and craniospinal dissemination. *Pathol Oncol Res* 1999; 5: 155-9.
42. Vasiljevic A, François P, Loundou A, et al. Prognostic factors in central neurocytomas: a multicenter study of 71 cases. *Am J Surg Pathol*. 2012; 36: 220-227.
43. Louis DN, Perry A, Reifenberger G. et al. The 2016 World Health Organization Classification of tumors of the central nervous system: a summary. *Acta Neuropathol*. 2016; 131(6): 803-820.
44. Johnson MO, Kirkpatrick JP, Patel MP, Desjardins A, Randazzo DM, Friedman HS, et al. The role of chemotherapy in the treatment of central neurocytoma. *CNS oncology*. 2019; 8(3):Cns41.
45. Sunil W. Dutta et al. Central neurocytoma: Clinical characteristics, patterns of care, and survival. *J Clin Neurosci*. 2018; 53: 106-111.