

# Annals of Clinical and Medical Case Reports

Research Article

ISSN 2639-8109 | Volume 7

## Metastasis to Brain and Lung in Carcinosarcoma of the Parotid Gland - A Case Report and Review of Literatures

Yang SH<sup>1,2</sup>, Buryanek J<sup>3</sup>, Guo S<sup>4</sup>, Karni RJ<sup>5</sup>, Shepard S<sup>1</sup>, Blanco A<sup>1</sup>, and Zhu JJ<sup>1\*</sup>

<sup>1</sup>The Vivian L. Smith Department of Neurosurgery, The University of Texas Health Science Center at Houston, Houston, Tex

<sup>2</sup>Department of Neurosurgery, St. Vincent's Hospital, College of Medicine, The Catholic university of Korea, Seoul, Republic of Korea

<sup>3</sup>Department of Pathology and Laboratory Medicine, The University of Texas Health Science Center at Houston, Houston, Tex

<sup>4</sup>Department of Internal medicine, Oncology Division, The University of Texas Health Science Center at Houston, Houston, Tex

<sup>5</sup>Department of Otorhinolaryngology-Head and Neck Surgery, The University of Texas Health Science Center at Houston, Houston, Tex

### \*Corresponding author:

Jay-Jiguang Zhu,  
The Vivian L. Smith Department of Neurosurgery,  
The University of Texas Health Science Center at  
Houston Medical School, 6400 Fannin Street, Suite  
2800, Houston, TX, 77030,  
E-mail: jay.jiguang.zhu@uth.tmc.edu

Received: 13 Aug 2021

Accepted: 02 Sep 2021

Published: 08 Sep 2021

### Copyright:

©2021 Zhu JJ. This is an open access article distributed under the terms of the Creative Commons Attribution License, which permits unrestricted use, distribution, and build upon your work non-commercially.

### Citation:

Zhu JJ, Metastasis to Brain and Lung in Carcinosarcoma of the Parotid Gland - A Case Report and Review of Literatures. *Ann Clin Med Case Rep.* 2021; V7(7): 1-4

### Keywords:

Carcinosarcoma; Parotid gland; Metastasis; Malignant mixed tumor; Brain

### Author Contributions:

SHY, JJZ, SS, AB, JB, SG, RJK, All these authors are contributed equally to this article

## 1. Abstract

Carcinosarcoma of the parotid gland is a rare and aggressive malignant mixed tumor in which carcinomatous and sarcomatous elements coexist and metastasize together. The tumor may occur in patients with previous or coexisting pleomorphic adenoma or may arise de novo of the parotid gland. We report the first case with carcinosarcoma of the parotid gland that developed brain metastasis. Our patient underwent the surgical resection of metastatic brain lesion and had adjuvant radiosurgery postoperatively. The prognosis of carcinoma with distant metastasis and the standard treatment have not been established yet. We summarize rare examples of carcinosarcoma of the parotid gland that metastasize to the distant organs.

## 2. Background

Malignant mixed tumors of the salivary glands are a broad term includes carcinoma ex pleomorphic adenoma (PA), benign metastasizing PA, and true malignant mixed tumor (carcinosarcoma) [1]. Of these tumors, carcinoma ex PA represents approximately 99% of cases [2]. Carcinosarcoma of the parotid gland is a very rare tumor composed of both malignant epithelial (carcinomatous) and malignant mesenchymal (sarcomatous) elements. It represents only 0.04 to 0.16% of salivary gland tumors and 0.4% of malignant salivary gland neoplasm [3,4].

nant salivary gland neoplasm [3,4].

We reviewed cases reported in literatures diagnosed with carcinosarcoma of parotid gland and developed distant metastasis. To our knowledge, this is the first case with carcinosarcoma of the parotid gland that developed brain and lung metastases as well as liver metastases on post mortem examination.

## 3. Case Presentation

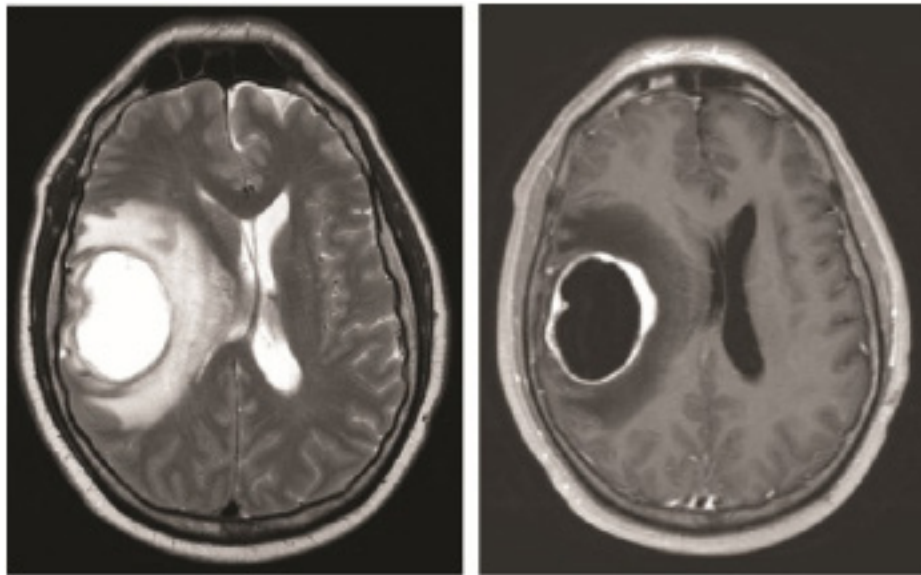
A 56-year-old male patient was presented to our department with the left hemiparesis. 16 months ago, he underwent the total parotidectomy on the left side with the sacrifice of the ipsilateral facial nerve. The lesion was 4.7 cm in the greatest dimension and showed both malignant stromal and epithelial components. Histopathological findings were consistent with a carcinosarcoma of the parotid gland. On sectioning, perineuronal invasion was noted. Lymphovascular invasion was not observed. He had adjuvant chemoradiation therapy. Six months later, pleural metastasis was found. The patient underwent stereotactic body radiotherapy to the left lung.

On the neurological examination, the motor power of the left extremities was grade 2 and the left facial palsy was noted with grade 2 according to House-Brackmann scale. The brain magnetic resonance images (MRI) showed a huge cystic lesion (44x51x40 mm) with a solid component in the right fronto-temporal region.

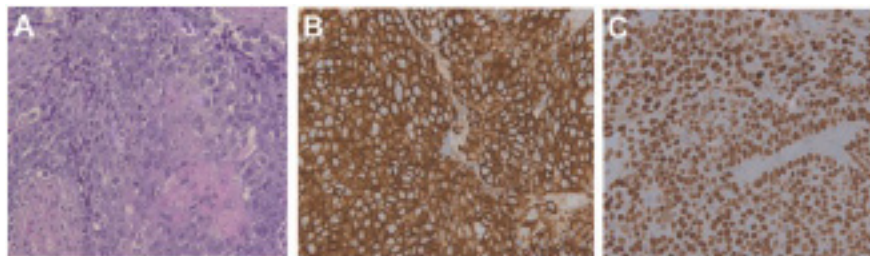
There was a midline shift and perilesional edema (Figure 1). He underwent craniotomy with tumor removal. After resection, his headache disappeared and the left hemiparesis improved to grade 4. Histopathological evaluation revealed squamous differentiation in the tumor. Highly positive immunostaining of Cam5.2 and p40 showed the evidence of squamous differentiation in this metastatic tumor. Cam5.2 is a low molecular weight cytokeratin and is expressed in a majority of the tumor, meaning that it is purely epithelial. The diffuse nuclear expression of p40 is consistent with the finding of squamous differentiation (Figure 2). The next-generation sequencing based assay identified the amplification of IRS2, CDK4, IGF1R, MDM2 and MYC genes in metastatic brain le-

sions. In primary parotid lesion, genomic alteration identified amplification of RAF1, CDK4, IGF1R, MDM2 and MYC genes.

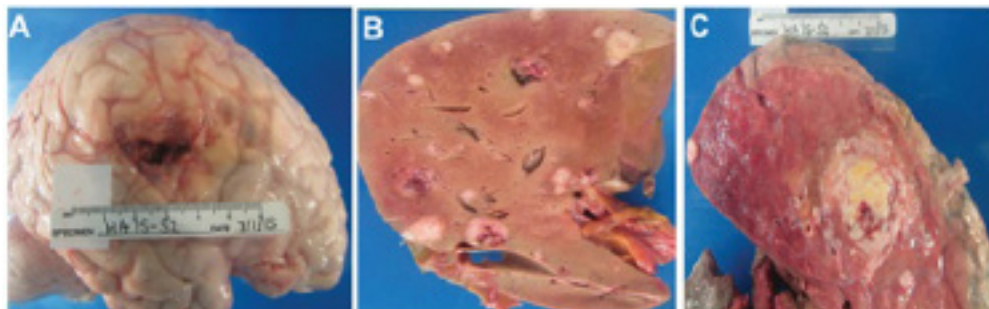
Postoperative radiosurgery was given to the remaining tumor mass. Three months later, new growth of tumor mass with increased intracranial pressure was noted. He went the second craniotomy for the treatment of growing intracranial lesion and brain edema. Eventually, 8 months after the diagnosis of brain metastasis, the patient died due to the progression of lung metastasis. The patient and his wife donated his body for autopsy (consent signed prior). Autopsy examinations showed postresectional changes in the brain and multiple metastatic lesions in the liver and lung (Figure 3).



**Figure 1:** Preoperative T2-weighted axial brain MR image (left) showing a lesion in the right fronto-temporal region. Gadolinium-enhanced T1-weighted MR image (right) demonstrating rim like enhancement.



**Figure 2:** Squamous differentiation of the metastatic brain tumor (H&E, x400) (A). Positive immunostaining of Cam5.2 (B) and p40 (C) demonstrating squamous differentiation of the lesion (x600).



**Figure 3:** Autopsy specimens revealing postsurgical cavity in the brain (A) and multiple metastatic lesions in the liver (B) and lung (C).

#### 4. Discussion

There are 3 histologic subtypes of malignant mixed tumors of the parotid gland. Carcinoma ex PA is the most common and consists of only a carcinomatous component. Carcinomatous transformation within a benign mixed tumor in which the initial benign elements are still identifiable is termed carcinoma ex PA. It has been thought to be indolent and slow-growing tumors. Carcinoma ex PA arises as a recurrence in a patient in whom a benign mixed tumor was previously resected. Metastasizing mixed tumor is the most infrequent subtype, occurring years after excision of the primary tumor or with a recurrence. Although no malignant features are identified within a benign mixed tumor, distant metastases occur. The histopathology of these metastatic lesions are also benign [5]. The true malignant mixed tumor, carcinosarcoma was first described in 1951 [6]. Carcinosarcoma is composed of both carcinomatous and sarcomatous elements. This is in contrast to the carcinoma ex PA in which only the epithelial element undergoes malignant transformation. One third of carcinosarcoma occur in patients with previous or coexisting Pas [7]. Hematogenous distant metastases have been reported to occur in as many as 44% of patients with carcinoma ex PA [8]. However, the metastasis to central nervous system (CNS) has been reported only in one case with carcinoma ex PA [9]. A 36-year-old man developed an end

stage complication of parotid PA, malignant conversion followed by diffuse CNS metastases. Clinically, carcinosarcomas are very aggressive. Local recurrence and metastasis via both lymphatic and hematologic pathways to local or regional sites are frequently seen in up to 50% of patients [10]. However, the distant metastasis of carcinosarcoma of the parotid gland has little been reported in English literature sources. Clinical manifestations of the patients with carcinosarcom of the parotid gland developing distant metastasis are summarized in Table 1. A 47-year old patient presented with a one-year history of an enlarging mass in the jaw which was then diagnosed with malignant mixed tumor [11]. However, she had the excision from the same area two times when she was 8 years old and 22 years. The possibility of benign PA gave rise to malignant mixed tumor could not be excluded. Other two patients had the history of coexisting PA in the parotid gland and developed pleural and pulmonary metastasis, respectively [12,13]. A 10-year-old boy was simultaneously diagnosed with orbital metastasis and carcinosarcoma of the parotid gland [14]. It is suggested that carcinosarcoma of the parotid gland developed de-novo. Similarly, our case was newly diagnosed with carcinosarcoma of the parotid gland without past history of PA. 16 months later, the metastatic brain lesion developed. He had the resection via craniotomy and adjuvant radiosurgery. Although the follow-up period was short, his neurologic recovery was impressive.

**Table 1:** Summary of carcinosarcoma of parotid gland developing distant metastasis

Ref. (year)	Age	Sex	Interval between diagnosis of parotid tumor to metastasis	Metastatic site	Treatment	Outcome
11 (1973)	47	F	2 years	Radius	Curettage	ND
14 (2004)	10	M	Simultaneously	Ocular	Chemotherapy (vincristine, etoposide, ifosfamide, doxorubicin) + radiotherapy + Enucleation	Disease free for 50 months
12 (2009)	47	M	2 yrs	Pleural	Chemotherapy (pemetrexed, cisplatin)	No progression for 11 months
13 (2009)	58	M	34 yrs	Pulmonary	ND	ND
The present case	56	M	16 months	Brain, lung, liver	Craniotomy (2 times) + radiosurgery	No progression (brain)

ND, not described

Several histogenetic theories of this tumor's origin exist. The first theory suggests that this entity may represent a collision tumor in which a carcinoma and a sarcoma form the independent and intermingle [15]. The next proposal suggests that a carcinoma provokes a reaction by the sarcoma-like connective tissue surrounding it that results in the characteristic findings. The third, and more widely accepted theory, suggests that the tumor is derived from dedifferentiated cells, pluripotent cells, or undifferentiated multipotent cells that are capable of divergent differentiation, resulting in a true malignant mixed tumor [16].

The next-generation sequencing analysis of 315 genes and introns of 28 genes found that the epithelial component of carcinosarcoma developed brain metastasis, accompanied with the gain of IRS2 amplification in this patient. IRS2 amplification was found in the

metastatic brain lesion, which was not noted in the primary parotid lesion. IRS2 encodes the insulin receptor substrate 2 which links insulin receptor activation to downstream effectors, including PI3K pathway. Both IRS1/2 are capable of inducing oncogenic transformation, lending further support to their role as oncogenes. Increased expression of IRS2 has been associated with increased cell migration in breast cancer cells and invasive bladder cancer. Recently, it is reported that IRS1/2 promotes the induction of epithelial-mesenchymal transition and cell proliferation in response to Wnt stimulation [17,18].

It is difficult to predict the prognosis of carcinosarcoma with limited follow-up. The mainstay of treatment is surgery with radiotherapy and possibly the addition of chemotherapy, although a definitive treatment protocol has not been concluded. It was

reported that surgery with radiation had a recurrence rate statistically significantly lower than surgical excision alone [19]. The benefits of chemotherapy are unclear. The child with ocular metastasis was initially treated with chemotherapy and radiotherapy. Because there was only partial response and the right eye had no light perception, the enucleation was performed [14]. Other patient received pemetrexed and cisplatin based chemotherapy with partial response after the misdiagnosis of a mesothelioma [12]. The survival rate for this tumor has been reported as 0% at 5 years [10]. The prognosis of carcinosarcom with distant metastasis is not known yet. Our patient died due to respiratory failure even though the metastatic brain lesion had stable disease. To our knowledge, this is the first report that developed brain metastasis in a patient diagnosed of carcinosarcoma of the parotid gland with the gain of IRS2 amplification.

## References

- Seifert G, Sobin LH. The World Health Organization's histological classification of salivary gland tumours: a commentary on the second edition. *Cancer*. 1992; 70(2): 379-386.
- Batsakis JG. Malignant mixed tumor. *Ann Otol Rhinol Laryngol*. 1982; 91(3): 342-343.
- Alvarez-Cañas C, Rodilla IG. True malignant mixed tumor (carcinosarcoma) of the parotid gland. Report of a case with immunohistochemical study. *Oral Surg Oral Med Oral Pathol Oral Radiol Endod*. 1996; 81(4): 454-458.
- Gnepp DR. Malignant mixed tumors of the salivary glands: a review. *Pathol Annu*. 1993; 28(1): 279-328.
- Batsakis JG. The pathology of head and neck tumors: nasal cavity and paranasal sinuses. *Head Neck Surg*. 1980; 2(5): 410-419.
- Kirklin JW, McDonald JR, Harrington SW, New GB. Parotid tumors; histopathology, clinical behavior, and end results. *Surg Gynecol Obstet*. 1951; 92(6): 721-733.
- Kwon MY, Gu M. True malignant mixed tumor (carcinosarcoma) of parotid gland with unusual mesenchymal component: a case report and review of the literature. *Arch Pathol Lab Med*. 2001; 125(6): 812-815.
- Olsen KD, Lewis JE. Carcinoma ex pleomorphic adenoma: a clinicopathologic review. *Head Neck*. 2001; 23(9): 705-712.
- Sheedy SP, Welker KM, DeLone DR, Gilbertson JR. CNS metastases of carcinoma ex pleomorphic adenoma of the parotid gland. *Am J Neuroradiol*. 2006; 27(7): 1483-1485.
- Tortoledo ME, Luna MA, Batsakis JG. Carcinomas ex pleomorphic adenoma and malignant mixed tumors. *Histomorphologic indexes*. *Arch Otolaryngol*. 1984; 110(3): 172-176.
- Jacobson ES, Jacobson HG, Batsakis JG. Malignant mixed tumor of parotid gland with a solitary metastasis to the radius. *J Oral Surg*. 1973; 31(7): 539-542.
- Khadse P, Prabhaskar K, Pramesh CS, Chaturvedi P, Shet T. Fine-needle aspiration biopsy of pleural metastases from a carcinosarcoma or true malignant mixed tumor of the parotid gland mimicking a mesothelioma. *Diagn Cytopathol*. 2009; 37(9): 680-685.
- Lin WC, Li CS, Lin CK, Hsu HH, Chang TH, Chen TY, et al. Atypical pulmonary metastases from a true malignant mixed tumor of the parotid gland. *Korean J Radiol*. 2009; 10(2): 202-205.
- Kiratli H, Soysal HG, Demir S. Orbital metastasis and intraocular invasion of malignant mixed tumor (carcinosarcoma) of the parotid gland in a child. *Arch Ophthalmol*. 2004; 122(1): 114-118.
- Ansari-Lari MA, Hoque MO, Califano J, Westra WH. Immunohistochemical p53 expression patterns in sarcomatoid carcinomas of the upper respiratory tract. *Am J Surg Pathol*. 2002; 26(8): 1024-1031.
- Bleiweiss IJ, Huvos AG, Lara J, Strong EW. Carcinosarcoma of the submandibular salivary gland. Immunohistochemical findings. *Cancer*. 1992; 69(8): 2031-2035.
- Geng Y, Ju Y, Ren F, Qiu Y, Tomita Y, Tomoeda M, et al. Insulin receptor substrate 1/2 regulates Wnt/ $\beta$ -catenin signaling through blocking autophagic degradation of dihevelled2. *J Biol Chem*. 2014; 289(16): 11230-11241.
- Park DH, Jeon HS, Lee SY, Choi YY, Lee HW, Yoon S, et al. MicroRNA-146a inhibits epithelial mesenchymal transition in non-small cell lung cancer by targeting insulin receptor substrate 2. *Int J Oncol*. 2015; 47(4): 1545-1553.
- Staffieri C, Marioni G, Ferraro SM, Marino F, Staffieri A. Carcinosarcoma de novo of the parotid gland. *Oral Surg Oral Med Oral Pathol Oral Radiol Endod*. 2007; 104(2): e35-40.