

## COVID-19-Associated Pneumothorax: Case Reports

Germana Lages Gandra, Fábio José Araújo do Carmo, Gustavo Pinto de Moraes Kiffer, and Ricardo Mesquita Camelo\* Hospital

Unimed Betim, Unimed-BH, Av. Juiz Marco Túlio Isaac, 3400 - Betim Industrial, Betim - MG, 32671-150, Brazil **ORCIDIDs:**

Germana Lages Gandra: <https://orcid.org/0000-0003-4712-4185>

Ricardo Mesquita Camelo: <https://orcid.org/0000-0001-9025-0289>

### \*Corresponding author:

Ricardo Mesquita Camelo,  
Hospital Unimed Betim, Unimed-BH, Av. Juiz  
Marco Túlio Isaac, 3400 - Betim Industrial,  
Betim - MG, 32671-150, Brazil,  
E-mail: [rmcamelo@hotmail.com](mailto:rmcamelo@hotmail.com)

Received: 21 Sep 2022

Accepted: 01 Sep 2022

Published: 07 Sep 2022

JShort Name: ACMCR

### Copyright:

©2022 Ricardo Mesquita Camelo. This is an open access article distributed under the terms of the Creative Commons Attribution License, which permits unrestricted use, distribution, and build upon your work non-commercially

### Keywords:

COVID-19; Spontaneous pneumothorax; Respiratory failure

### Citation:

Gandra et al, COVID-19-Associated Pneumothorax: Case Reports. Ann Clin Med Case Rep. 2022; V9(17): 1-5

### Abstract

Spontaneous pneumothorax associated with COVID-19 is rare. We reported four cases and reviewed the literature. Among the reports, 29% and 42% were a-/oligosymptomatic or symptomatic but improving, respectively. Clinicians must be aware of this complication because it can happen when the patient with COVID-19 was a-/oligosymptomatic or had improving symptoms.

### 1. Introduction

Pneumothorax is the presence of air in the pleural space due to communications between the pleural and the alveolar/external spaces or the presence of gas-producing organisms in the pleural space. Spontaneous pneumothorax (SP) is diagnosed when no injury has been inflicted to the thorax. There are two types of SP: primary SP, without apparent underlying lung disease, and secondary SP, when there is a clinically apparent disease. SP is a rare event among people with severe acute respiratory syndrome coronavirus 2 (SARS-CoV-2) pneumonia or COVID-19.<sup>1</sup> We described four cases of COVID-19-associated SP in patients treated at our hospital.

### 2. Case Reports

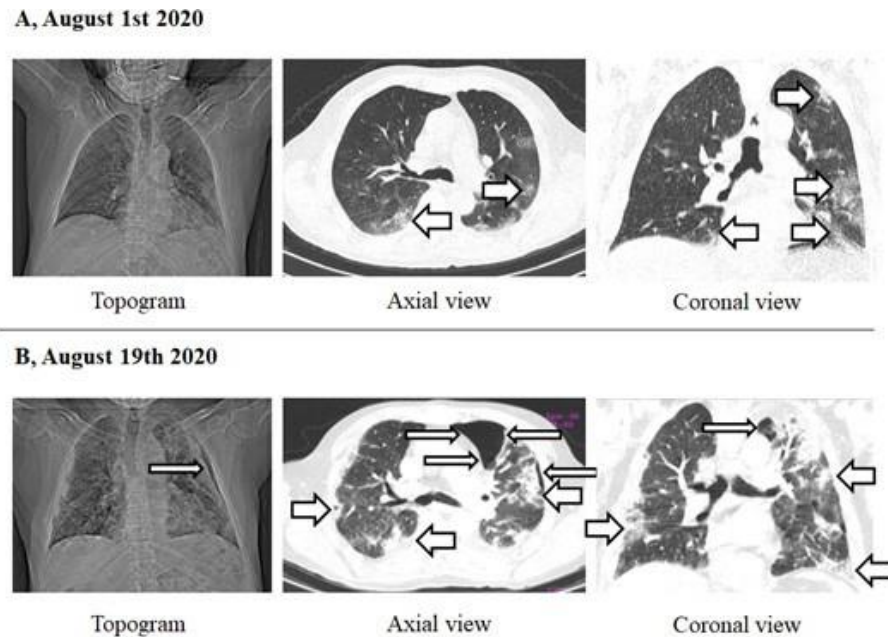
The study was approved by the Committee on Ethics on Research of the Hospital Eduardo de Menezes. Between March/1/2020-June/30/2021, we prospectively searched all patients hospitalized because of SP during or after COVID-19. The enrolled patients signed the Consent Form. COVID-19 was diagnosed by reverse

transcriptase polymerase chain reaction for SARS-CoV-2 from nasopharyngeal swab. We defined SP as pneumothorax detected by any imaging modality without previous positive-pressure ventilation, neck/chest manipulation, or trauma. We collected data using a standardized form.

### Case 1

An 84-year-old man with motor sequelae of stroke, hyperlipidemia, mood disorder, benign prostatic disease, and previous smoker presented to the Emergency Department (ED) with one-day fever, cough, and dyspnea. He was afebrile, tachypneic with mild breathing effort, normal lung sounds, and desaturating. He was discharged home three days before, after a two-week hospitalization due to COVID-19 and complaining fever, dry cough, and diarrhea.

During this hospitalization, his chest computed tomography (CT) evidenced ground-glass opacities in 50% of the lung parenchyma (Figure 1A). He received oxygen by nasal cannula, dexamethasone, amoxicillin-clavulanate, azithromycin, and enoxaparin. Upon his return, he had elevated reactive C-protein (RCP). Other laboratory tests were unremarkable. The new chest CT evidenced sparse ground-glass opacities, and a small left-sided pneumothorax with bilateral small pleural effusion (Figure 1B). He received oxygen by nasal cannula, and dexamethasone was reintroduced. He received piperacillin-tazobactam and thromboprophylaxis. Pneumothorax was treated conservatively. He was discharged home after one week.



**Figure 1:** Chest computed tomography (CT) of the Case #1. A. Chest CT (topogram, axial view, and coronal view) of the first hospitalization. Some ground-glass opacities were highlighted by large white arrows. B. Chest CT (topogram, axial view, and coronal view) of the second hospitalization, when left-sided pneumothorax was diagnosed (thin white arrows). Some ground-glass and confluent opacities were also highlighted by large white arrows.

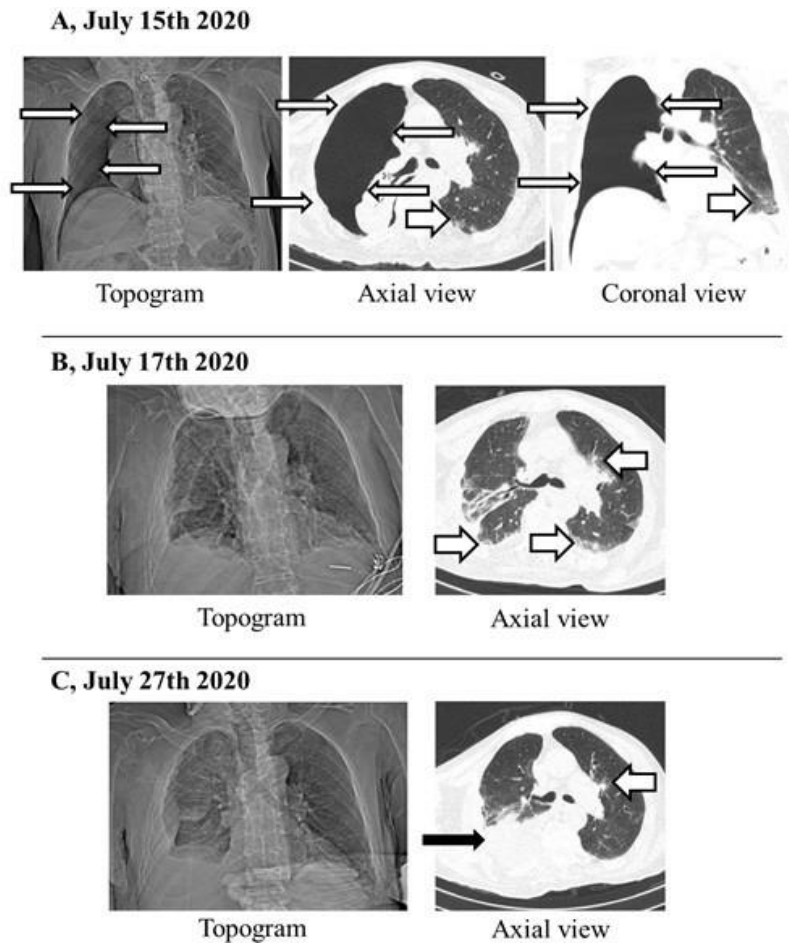
## Case 2

A 77-year-old man with dementia and stroke sequelae presented to the ED with COVID-19 after one day of agitation, without cough. He stopped smoking for approximately 30 years. He was afebrile, with normal lung sounds, tachypneic and desaturating, tachycardic, and mildly hypertensive. He had leucocytosis, with elevated RCP, lactic acid, and lactic dehydrogenase. Other laboratory tests were unremarkable. Ground-glass opacities covered less than 25% of the lung parenchyma, with a larger right-sided pneumothorax and collapse of the right lung (Figure 2A). A chest drain was inserted with a water-seal. He received oxygen by face mask, amoxicillin+clavulanate, azithromycin, dexamethasone, and enoxaparin. Clinical conditions improved and the follow-up chest CT confirmed lung expansion, with right-sided pleural effusion and bilateral consolidations (Figure 2B). The drain was removed three days after insertion. One week after hospitalization, his respiratory condition worsened. He was afebrile with leucocytosis and increased RCP. A new chest CT evidenced sparse ground-glass opacities, but a larger pleural effusion associated with pleural thickness (Figure 2C). Pleural decortication was performed, and piperacillin+tazobactam and teicoplanin were prescribed. Vancomycin was prescribed, due to *Staphylococcus haemolyticus* vancomycin-sensitive on a catheter tip culture. Fluconazole was associated, due to skin candidiasis on seborrheic dermatitis. Since fever was recurrent and he started diarrhea, a new course of piperacillin+tazobactam with metronida-

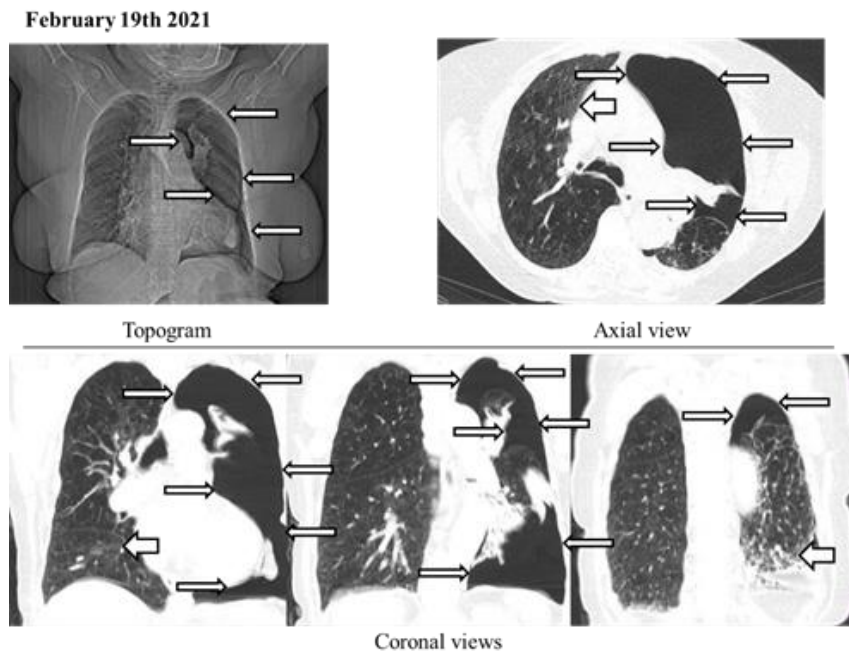
zole was initiated, with *Saccharomyces boulardii* and racecadotril. *Clostridium difficile* glutamate dehydrogenase was negative. *Klebsiella pneumoniae* spp. *pneumoniae* and *Pseudomonas aeruginosa* amikacin-sensitive were identified on the culture of his calcaneus tissue injury, and he received amikacin. He was discharged home after 86 days of hospitalization.

## Case 3

A 67-year-old woman presented to the ED complaining fever, confusion, dizziness, dry cough, and tachypnea, in the last seven days. She had lung emphysema due to previous smoking with oxygen supplementation at least three-quarters of the daytime. She was treating systemic arterial hypertension, dyslipidemia, hypovitaminosis D, and hypothyroidism. She also had a hearing sequela due to previous stroke. She had mild COVID-19 two months before. She was afebrile, dyspneic with moderate effort, desaturating at room air, and hypertensive. Laboratory tests were unremarkable. SARS-CoV-2 was not detected. Chest CT evidenced a centrolobular emphysema and a large left pneumothorax with a mild right-deviated mediastinum (Figure 3). Low-flow oxygen was provided, and she received azithromycin and piperacillin+tazobactam, corticosteroids, bronchodilators, codeine, and thromboprophylaxis. A chest drain was inserted, connected to a water-seal. Bullectomy and pleurodesis were performed 5 days after tube insertion, because of a high-flow air drainage. Chest tube was removed 5 days later. She was discharged home after 14 days of hospitalization.



**Figure 2.** Chest computed tomography (CT) of the Case #2. A. Chest CT (topogram, axial view, and coronal view) at hospitalization, when right-sided pneumothorax was diagnosed (thin white arrows). Some ground-glass opacities were highlighted by large white arrows. B. Chest CT (topogram and axial view) showing lung expansion after chest tube insertion and air drainage. Some ground-glass opacities were also highlighted by large white arrows. C. Chest CT (topogram and axial view) evidencing sparse ground-glass opacities (large white arrow), and a larger pleural effusion associated with pleural thickness (thin black arrow).

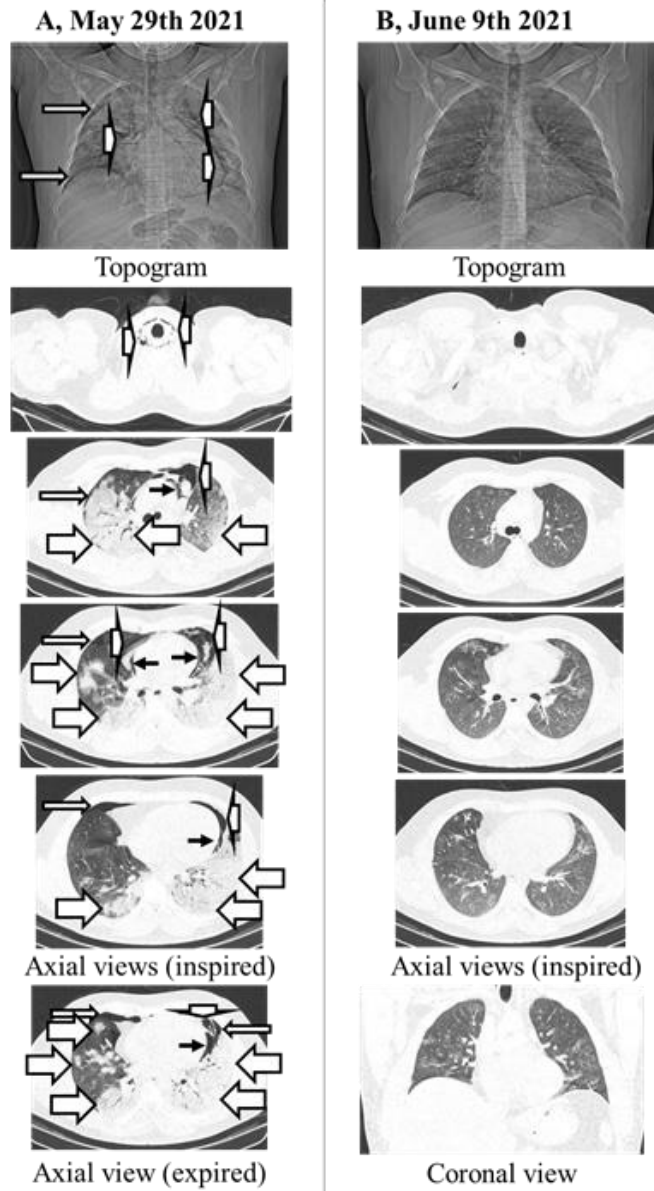


**Figure 3.** Chest computed tomography (CT) of the Case #3. Chest CT (topogram, axial view, and coronal view) at hospitalization, when right-sided pneumothorax was diagnosed (thin white arrows). Some ground-glass opacities were highlighted by large white arrows.

**Case 4**

A previously healthy 22-year-old man with COVID-19 was admitted after one week of sore throat and dry cough. At admission, he was dyspneic with moderate effort, desaturating, tachycardic, and normotensive. He denied smoking. He had elevated RCP. The other blood tests were unremarkable. Chest CT showed ground-glass opacities covering more than 50% of the lung parenchyma and few consolidation foci (Figure 4A). A mild-to-moderate bilateral pneumothorax associated with pneumomediastinum and

pneumopericardium was also noted. Oxygen was offered by face mask. He received dexamethasone, thromboprophylaxis, and amoxicillin+clavulanate and azithromycin. His respiratory effort worsened, and he was intubated and mechanically ventilated in prone position. Two chest tubes were inserted in both his right and left hemithoraces, all connected to water-seals. Chest tubes were withdrawn after four days. He self-extubated three days later. He was discharged home, with a normal chest CT and breathing at room air (Figure 4B).



**Figure 4.** Chest computed tomography (CT) of the Case #4. A. Chest CT (topogram and both inspired and expired axial views) at hospitalization, when bilateral pneumothoraces were diagnosed (thin white arrows). Pneumomediastinum (large-narrow white arrows) and pneumopericardium (black arrows) were also detected. Some ground-glass opacities were highlighted by large-long white arrows. B. Chest CT (topogram, axial, and coronal views) before discharge. Small volume of gas was noted in the upper thorax. The other pneumatoses resolved completely.

### 3. Discussion

Since the beginning of the pandemic, many cases of COVID-19-associated SP were reported. SARS-CoV-2 causes a diffuse alveolar damage with perivascular immune cell infiltration, severe endothelial injury, and widespread thrombosis, which may lead to air leak and dilatation of some alveoli and hemorrhagic/ edematous collapse of others.<sup>2</sup> The final rupture of the alveolar wall is a consequence of shear stress (e.g., coughing), developing a communication with the pleural space. Ultimately, COVID-19 may also be considered a cause of SP. However, it should be highlighted it is an unusual complication of COVID-19 (relative frequency of 0.57%), although more common in affected than in non-affected individuals.<sup>1,2</sup> A recent case-control study described 40 COVID-19-associated SP (i.e., without previous positive-pressure ventilation, chest manipulation or trauma) among 71,904 patients attending in 50 Spanish EDs.<sup>3</sup> Patients with COVID-19 who developed SP more frequently were men and their median ages similar to our search.<sup>3</sup> They also more frequently had dyspnea/ tachypnea and chest pain, desaturation, and increased leukocyte count, than those without COVID-19.<sup>3</sup> Another registry held in 16 centers in the United Kingdom which reported 20 patients with COVID-19-associated SP.<sup>4</sup> Nine patients had the diagnosis of pneumothorax at presentation to the ED, from which five were readmissions.<sup>4</sup> All cases we described had the diagnosis of pneumothorax at admission, after improving or complaining mild symptoms.

### 4. Conclusion

COVID-19-associated SP is a potentially severe, although rare, complication. Physicians should be aware of this important pneumatoxis because it can happen in people without previous diag-

### References

1. Miro O, Llorens P, Jiménez S. Frequency of five unusual presentations in patients with COVID-19: Results of the UMC-19-S1. *Epidemiol Infect.* 2020; 148: e189-92.
2. Menter T, Haslbauer JD, Nienhold R. Postmortem examination of COVID-19 patients reveals diffuse alveolar damage with severe capillary congestion and variegated findings in lungs and other organs suggesting vascular dysfunction. *Histopathology.* 2020; 77(2):198-209.
3. Miro O, Llorens P, Jiménez S. Frequency, Risk Factors, Clinical Characteristics, and Outcomes of Spontaneous Pneumothorax in Patients With Coronavirus Disease 2019: A Case-Control, Emergency Medicine-Based Multicenter Study. *Chest.* 2021; 159(3): 1241-1255.
4. Martinelli AW, Ingle T, Newman J. COVID-19 and pneumothorax: A multicentre retrospective case series. *Eur Respir J.* 2020; 56(5):2002697.